


IS AND OSTITIS OF THE SYMPHYSIS AND THE PUBIS FOLLOWING SUPRAPUBIC CYSTOTOMIES

BY
EDWIN BEER
New York, N. Y.



83
B
16



PERIOSTITIS AND OSTITIS OF THE SYMPHYSIS AND RAMI OF THE PUBIS FOLLOWING SUPRAPUBIC CYSTOTOMIES

EDWIN BEER

New York, N. Y.

Received for publication December 21, 1927

During the last dozen years, following suprapubic operations on the bladder we have repeatedly observed a curious and painful complication of periostitis involving the bones of the pelvis, starting usually in the bodies of the pubic bones. This complication has usually developed sometime after the third week, and to the uninitiated presents a very puzzling picture.

In the literature, as far as I have been able to gather, there are practically no references to this condition except a brief mention by H. Cabot in the "System of Urology," which he edited.¹ This is very striking, as only patients whose bladders have been opened seem to develop this complication. In gynecological suprapubic incisions, in which the bladder is not opened, no such complicating periostitis seems to have been observed.

The exact cause of this periostitis is a little difficult to define. It is apparently a mild infection secondary to the bladder operation, and has been seen following suprapubic prostatectomy and suprapubic operations on the bladder for neoplasms. It is surely a rare complication, though we have seen every year one or more cases during the last twelve years. Whether the infection develops in the periosteum as a result of injury to the periosteum by traction on the attached rectus muscles, or whether it is due to direct bruising of the periosteum by drainage tubes in the bladder, is difficult to say. Surely it would seem that the former is the more likely explanation, as every attempt has been made to protect the symphysis from pressure by the suprapubic tube.

¹Also E. Beer, *International Journal of Medicine and Surgery*, May, 1924.

The clinical picture of this condition is very striking. The patients complain of pain when they try to sit up or when they cough, due to the fact that the rectus muscles pull against the

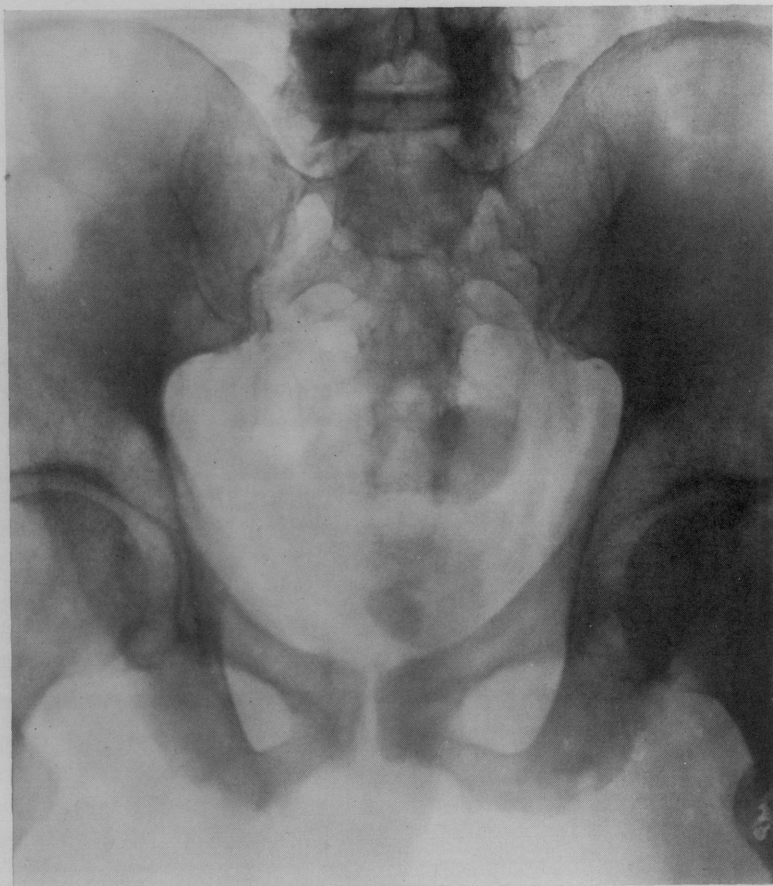

FIG. 1. J. K., CASE 1. OSTEOPERIOSTITIS OF PELVIC BONES FOLLOWING SUPRAPUBIC CYSTOSTOMY

sensitive, inflamed attachment at the symphysis. Some of the cases seem to be very mild, and the trouble becomes localized at the attachment of the rectus muscles; but in the majority the process seems to extend without any febrile reaction down along

the descending ramus of the pubis, so that the patients have pain and tenderness along the attachment of the adductor muscles which interferes with their walking and with the separation of the two thighs. This disturbance may last for several months, so that the patients walk like cripples, continually complaining of pain on moving the legs even after the original pain at the

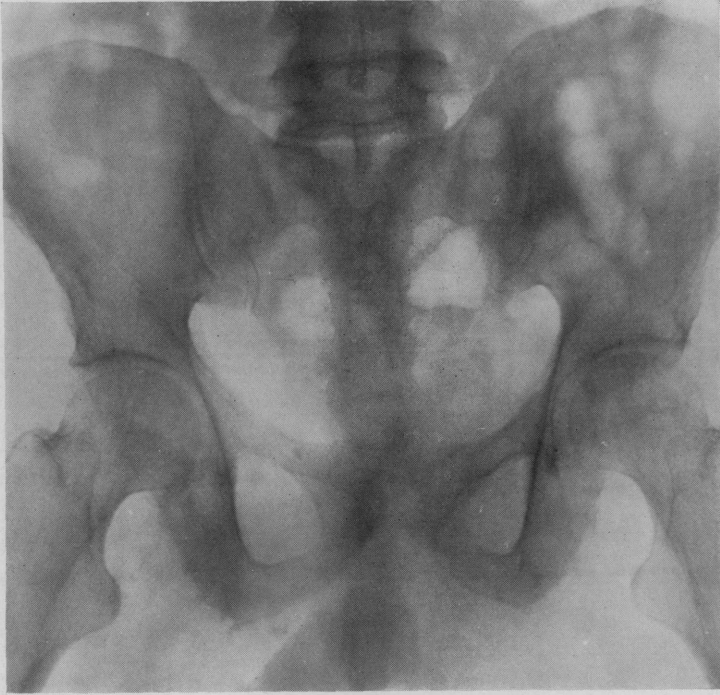

FIG. 2. J. K., CASE 2. OSTEOPERIOSTITIS OF PELVIC BONES FOLLOWING SUPRAPUBIC CYSTOSTOMY

attachment of the rectus muscles has disappeared. Finally under more or less appropriate treatment together with time, the process seems to go on to resolution, and the patients are perfectly well.

The physical signs in these cases are very slight. They are tenderness on palpation of the body of the pubis, as well as the

descending ramus down to the ischium; and providing the process has been fully developed, an x-ray of the pubis would show a fraying of the periosteum along the descending ramus, with perhaps areas of absorption at the symphysis and in the descending ramus, as well as the body of the ischium. The x-ray is usually far from conclusive in the early stages, though in the advanced stage it may be very definite, and even look like metastatic growths in the bones, as there are developed in some of the advanced cases definite areas of absorption which are due to osteitis, and not due to neoplasm.

The first case of this condition that I personally encountered was in 1916, following a simple suprapubic prostatectomy. About three weeks after the operation the patient developed pain over the symphysis and down the adductor muscles, with tenderness over the attachment of the rectus muscles and adductor muscles. As the suprapubic fistula was slow in healing, I had feared he might have had a foreign body left behind, until it became evident as the wound closed completely, that the symphysis and adjacent bones were involved in the periostitis, which gradually cleared up under local heat, and Sitz baths, plus massage and baking.

Since the first case just mentioned there have been numerous other similar cases, and this year again at one time I happened to observe 2 similar cases following resection of the bladder for carcinoma. Both the case of 1916 and those seen in the intervening period, as well as the last 2 cases, have gradually improved and gotten over all their symptoms. It is evident from the above that if one fails to appreciate this clinical entity, one may go astray in interpreting all the disability that these patients may complain of. Moreover, if one relies upon the x-ray study alone, one may readily come to the conclusion that one is dealing with a secondary malignancy of the bones of the symphysis and pelvis.

THE JOURNAL OF UROLOGY
VOLUME XX, NUMBER 2, AUGUST, 1928

CONTENTS

Presidential Address. Twenty-five Years After. RICHARD F. O'NEIL.....	147
The Surgical Pathology of Malformations in the Kidneys and Ureters. JAMES E. DAVIS.....	155
The Apparent Disappearance of Pulmonary Metastasis in a Case of Hypernephroma Following Nephrectomy. HERMON C. BUMPUS, JR.....	185
Traumatic Rupture of Left Kidney. Case Report. AUGUSTUS HARRIS.....	193
Suprarenal-Renal Heterotopia. Report of a Case. HAROLD D. CAYLOR.....	197
Papillary Carcinoma of the Kidney with Cystic Formation, Containing Over Eight Liters of Fluid. GEORGE F. CAHILL AND HAROLD H. GILE.....	203
Muciparous Glands in the Mucosa of the Urinary Bladder. Report of Two Cases. LEO EDELMAN.....	211
The Sedimentation Test in Urology. HEINRICH L. WEHRBEIN..	225
Periostitis and Ostitis of the Symphysis and Rami of the Pubis Following Suprapubic Cystotomies. EDWIN BEER.....	233
The Value of Vas Injection in Chronic Genital Infections Based Upon a Series of 75 Cases. THEODORE BAKER.....	237
Comparison of the Results of Various Treatments for Acute Gonorrheal Epididymitis. ERIC STONE.....	245
Exostoses Occurring on the Os Calcis as the Result of Gonococcal Infection. H. KING WADE.....	259